Radiology Case Reports 13 (2018) 709–712

Available online at www.sciencedirect.com

ScienceDirect

journal homepage: http://Elsevier.com/locate/radcr

Gastrointestinal

Advanced parametric imaging for evaluation of Crohn's disease using dual-energy computed tomography enterography

Narumi Taguchi MD[a], *Seitaro Oda MD, PhD*[a,*], *Tateaki Kobayashi MD*[b], *Hideaki Naoe MD, PhD*[b], *Yutaka Sasaki MD, PhD*[b], *Masanori Imuta MD, PhD*[a], *Takeshi Nakaura MD, PhD*[a], *Yasuyuki Yamashita MD, PhD*[a]

[a] *Department of Diagnostic Radiology, Faculty of Life Sciences, Kumamoto University, 1-1-1 Honjyo, Chuo-ku, Kumamoto, 860-8556, Japan*

[b] *Department of Gastroenterology and Hepatology, Faculty of Life Sciences, Kumamoto University, 1-1-1 Honjyo, Chuo-ku, Kumamoto, 860-8556, Japan*

ARTICLE INFO

Article history:
Received 17 January 2018
Accepted 2 April 2018
Available online 24 April 2018

Keywords:
Crohn's disease
CT enterography
Dual-energy CT

ABSTRACT

We describe a case of small bowel Crohn's disease in which dual-energy computed tomography enterography using dual-layer spectral detector scanner contributed to quantitative assessment, and provided a higher degree of confidence pertaining to the diagnosis. Dual-layer spectral detector computed tomography enables retrospective analysis including virtual monochromatic imaging, iodine mapping, and determining the effective atomic number Z with routine scan protocols. These advanced parametric dual-energy imaging holds promising potential as an imaging biomarker for diagnosis, risk-stratification, monitoring of disease progression and therapy, and outcome prediction.

© 2018 the Authors. Published by Elsevier Inc. under copyright license from the University of Washington. This is an open access article under the CC BY-NC-ND license (http://creativecommons.org/licenses/by-nc-nd/4.0/).

Introduction

Crohn's disease is a chronic inflammatory process that affects various parts of the gastrointestinal tract with an unknown etiology, which most commonly affects young people in late adolescence and early adulthood [1]. Imaging has played crucial roles not only in diagnosis but also in management of patients with Crohn's disease, as it characteristically undergoes recurrent relapses and remissions [2]. The development of computed tomography (CT) technique in the recent years has made CT enterography emerge as the mainstream diagnostic tool in the evaluation of small-bowel diseases [3,4]. The major advantages of CT enterography are its noninvasive nature and a comprehensive evaluation of both enteric and especially extra-enteric abnormalities. Although CT enterography has shown high sensitivity in the diagnosis of small bowel Crohn's disease, several of the most common signs are nonspecific, including bowel wall thickening, increased perienteric fat attenuation, and bowel wall hyperenhancement [4]. Bowel wall hyperenhancement is the reliable sign for active Crohn's disease, but these findings are often subtle and difficult to identify with confidence.

* *Corresponding author.*
E-mail address: seisei0430@nifty.com (S. Oda).

https://doi.org/10.1016/j.radcr.2018.04.002

1930-0433/© 2018 the Authors. Published by Elsevier Inc. under copyright license from the University of Washington. This is an open access article under the CC BY-NC-ND license (http://creativecommons.org/licenses/by-nc-nd/4.0/).

Dual-energy CT is an imaging technique based on data acquisition at 2 different energy settings. This technique is widely used in cardiovascular imaging, especially for pulmonary embolism work-up but is now also increasingly developed in the field of abdominal imaging [5]. Dual-energy postprocessing methods of iodine-selective imaging (iodine mapping) and virtual monochromatic imaging have the broadest applicability in clinical imaging. These imaging methods are particularly useful for situations in which subtle differences in contrast enhancement may have important clinical implications. There is a greater difference in attenuation between normal and abnormal perfused tissue at lower energy levels in virtual monochromatic imaging, which results in improved clarity pertaining to the hyperenhancement of tissues, such as those of the active Crohn's disease. Furthermore, iodine mapping can be used to quantitatively measure bowel wall enhancement based on estimated iodine concentrations at designated regions of interest. This can further increase confidence pertaining to the degree of altered enhancement and is of potential benefit to patients with Crohn's disease. Recently, the novel detector-based dual-energy CT system called dual-layer spectral detector CT became commercially available (iQon Spectral CT; Philips Healthcare, Best, the Netherlands). The instrument uses a single x-ray source and acquires dual-energy information by measuring the low-energy regions of the emitted spectrum through the upper layer of the detector, and high-energy photons penetrate this layer and are measured in by the deeper layer of the detector [6]. This new technology facilitates the simultaneous acquisition of low- and high-energy data at exactly the same spatial position, and the dual-energy information is retrospectively available for every scan with routine protocols. This technique may improve diagnostic confidence in CT enterography.

Here, we describe a case of small bowel Crohn's disease in which dual-energy CT enterography using dual-layer spectral detector scanner contributed to quantitative assessment as an imaging biomarker.

Case report

A 73-year-old male presented with abdominal pain, diarrhea, and weight loss. Based on clinical, radiological, endoscopic, and histological findings, he was diagnosed with small bowel Crohn's disease. Standard infliximab induction therapy was commenced, and there was a significant symptomatic and biochemical improvement. However, after approximately 8 years of symptom-free remission, his symptoms began to return, and he was admitted to our hospital. His abdomen was soft with mild right-sided tenderness. Laboratory studies showed only slight inflammatory signs (C-reactive protein, 2.48 mg/dL). We considered a relapse of Crohn's disease and performed CT enterography using a dual-layer spectral detector CT system with a standard scan protocol [7,8]. The standard contrast material dosage (600 mgI/kg) was delivered at a rate of 3 mL/s, and the scanning was initiated 45 seconds (enteric phase) and 85 seconds (delayed phase) after contrast material injection. The scan parameters were as follows: detector configuration, 64×0.625 mm; gantry rotation time, 0.5 seconds; helical pitch (beam pitch), 0.797; tube voltage, 120 kVp; tube current–time product, 124 mAs (effective mAs) with automodulation; and volume CT dose index, 11.6 mGy and 10.4 mGy for the enteric and delayed phases, respectively. The initial CT scan revealed strictures with wall thickening and abnormal enhancement patterns on the right side of the small bowel (ileum) and mild dilatation of the intervening segments with normal thickness and enhancement patterns (Fig. 1A). Based on these findings, Crohn's disease with an actively inflamed small bowel was suspected. For more confidence in the diagnosis, we performed retrospective dual-energy analyses of the enteric phase image data using a thin-client workstation (Spectral Diagnostic Suite; Philips Healthcare, Best, the Netherlands). Virtual monochromatic 40-keV images created with the dual-energy data showed better contrast attenuation between the inflamed and non-inflamed segments than the conventional images (Fig. 1b). The parametric analysis of iodine density mapping revealed iodine levels of 2.8 mg/mL in the inflamed bowel segment and 1.3 mg/mL in the normal segment (Fig. 1C). The effective atomic numbers (Z_{eff}) of the inflamed and normal bowel segments were 8.7 and 7.8, respectively, indicating that the inflamed segment contained more iodinated contrast than the normal segment (Fig. 1D). We confidently diagnosed a relapse of Crohn's disease in the ileum. Subsequent retrograde (anal approach) double-balloon enteroscopy confirmed active mucosal inflammation, edema, and the stricture in the distal ileum.

The patient continued taking mesalamine 2 g daily and was started on controlled ileal release budesonide 9 mg daily with significant symptomatic improvement. Follow-up CT enterography 2 months after initiating this therapy showed that the strictures with wall thickening and abnormal enhancement patterns in the ileum were improved. The iodine level in the ileum lesion had also decreased to 1.5 mg/mL, which was equivalent to the level in the normal small bowel wall (Fig. 2).

Discussion

CT enterography is a noninvasive imaging test that uses a neutral intraluminal contrast medium and an intravenous contrast medium to assess small bowel disorders, particularly the extent and severity of Crohn's disease [3]. CT enterography is now becoming the first-line modality for the evaluation of suspected Crohn's disease. CT enterography has also become an important alternative to traditional fluoroscopy in the assessment of small bowel disorders.

Thanks to a simultaneous acquisition at high and low energy x-ray datasets, dual energy CT can achieve material-based decomposition and reconstruct parametric images. That can facilitate a higher level of material characterization than conventional single-energy CT. The dual-layer spectral detector CT scanner is a newest type of dual-energy CT system, and have commercially introduced in 2016. With this new technology the dual-energy information is retrospectively available for every scan by following the usual protocols, and no a *priori* decision on the suitability or need of dual-energy acquisition before the examination is needed; the other conventional tube-based dual-energy CT system (dual-source system, fast kVp switching system, and sequential 2-scan system) require a

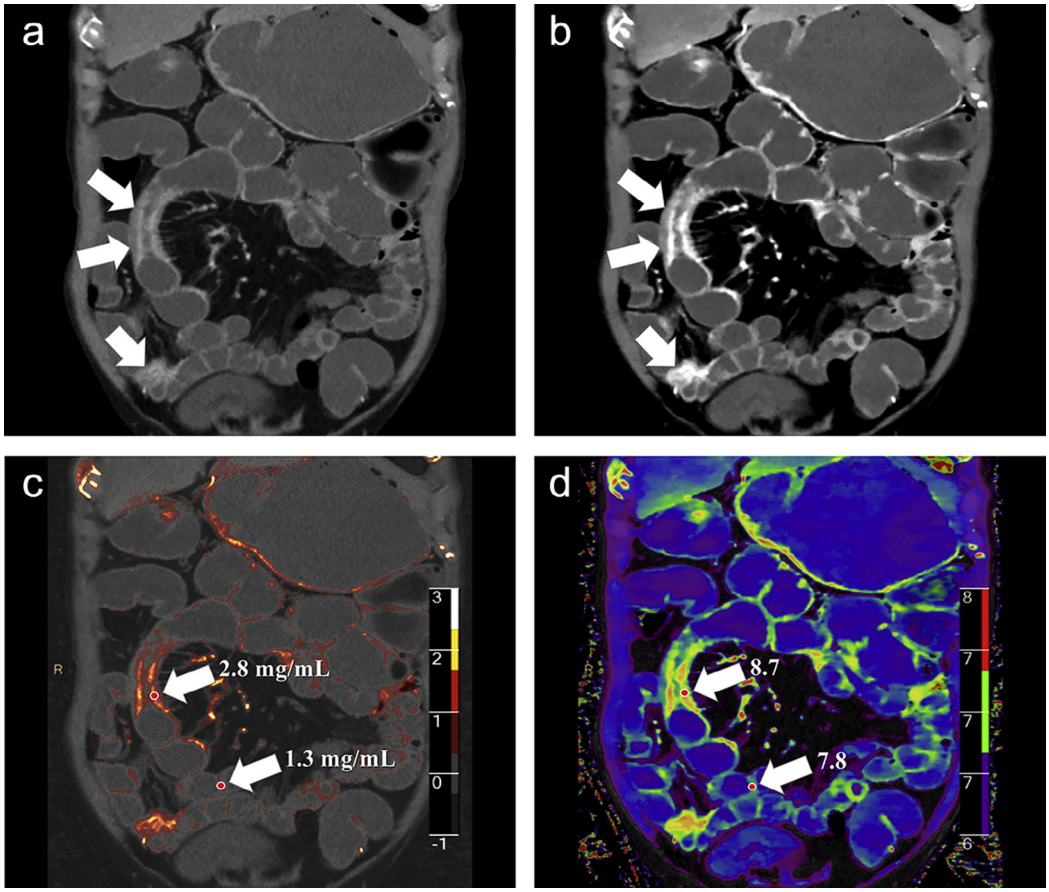

Fig. 1 – Computed tomography enterography images showing an actively inflamed small bowel due to Crohn's disease in the right abdomen (arrows). The inflamed segments with abnormal wall enhancement are less evident on the conventional image (A) than on the virtual monochromatic 40-keV image (B). An iodine map (C) shows iodine levels of 2.8 mg/mL in the inflamed bowel segment and 1.3 mg/mL in the normal segment. The effective atomic numbers of the inflamed and normal segments were 8.7 and 7.8, respectively (D).

prescan determination of use that makes it difficult to use them in routine clinical practice.

We have demonstrated that, compared with conventional CT enterography alone, retrospective analysis of dual-energy CT enterography, performed using a dual-layer spectral detector CT system, improved clarity and confidence in the diagnosis of small bowel Crohn's disease. Dual-energy analyses included virtual monochromatic imaging and parametric imaging (iodine density mapping and effective atomic number mapping). Virtual monochromatic imaging and iodine density mapping are the dual-energy analysis techniques with the broadest application in clinical practice. Attenuation of iodine is increased at lower energy levels (e.g., 40-keV) predominantly due to the photoelectric effect [9]. Therefore, high iodine-containing tissue becomes hyper-attenuated at low energy levels in virtual monochromatic imaging [10]. This difference in attenuation between high and low iodine-containing tissues at low energy levels could improve imaging clarity in Crohn's disease. Iodine density mapping allowed a qualitative assessment of iodine levels in the tissue, and estimated iodine concentrations (mg/mL) could be calculated and displayed in color. Iodine density mapping also has the potential to improve confidence in the identification of actively inflamed small bowel due to Crohn's disease and to enable the quantitative evaluation of severity. Dual-energy analysis can also provide Z_{eff}, which may enhance tissue characterization leading to new quantitative diagnostic parameters. The distinction between inflammatory and fibrostenotic strictures is clinically relevant due to the different management strategies employed. In this case, the CT images were acquired at the enteric and delayed phases based on previous reports [7,8]. Although we performed the dual-energy analysis using the enteric phase images in this case, additional dual-energy analysis using the delayed phase images may provide fibrotic lesion information that are emphasized more in this phase. This could aid in discriminating between active inflammation and the fibrotic lesions or assessing the coexistence of these 2 conditions.

Because many patients with Crohn's disease are young, the radiation exposure in CT enterography should be minimized and carefully monitored, and radiation dose reduction techniques, including automatic exposure control and iterative image reconstruction algorithms, should be employed.

Thus, advanced parametric dual-energy imaging might hold promising potential as an imaging biomarker for diagnosis, risk-stratification, monitoring of disease progression and therapy, and outcome prediction. However, further investigations are

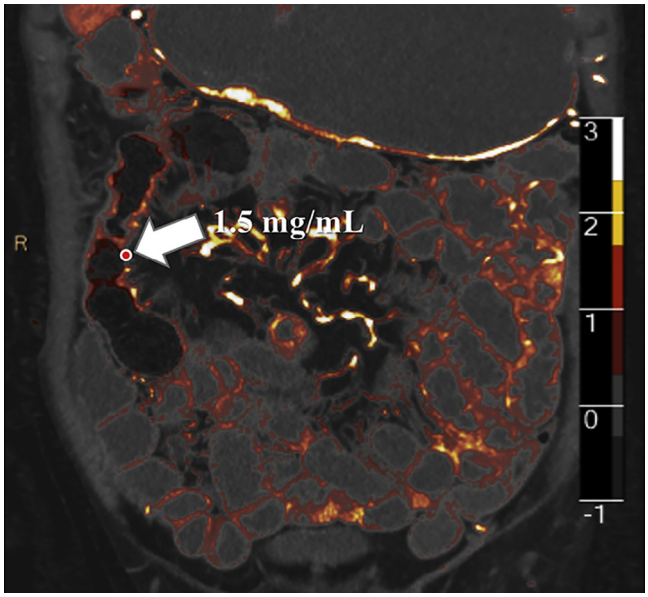

Fig. 2 – An iodine map of the follow-up computed tomography enterography at 2 months after the initiation of the new therapy regimen demonstrates improvement in the ileac lesions and an iodine level of 1.5 mg/mL, which is equivalent to the level in the normal small bowel wall.

warranted for confirmation. To the best of our knowledge, this is the first patient with Crohn's disease to have undergone parametric dual-energy analysis performed on a dual-layer spectral detector CT system, a new dual-energy CT system.

REFERENCES

[1] Baumgart DC, Sandborn WJ. Crohn's disease. Lancet 2012;380(9853):1590–605.
[2] Gajendran M, Loganathan P, Catinella AP, Hashash JG. A comprehensive review and update on Crohn's disease. Dis Mon 2017.
[3] Paulsen SR, Huprich JE, Fletcher JG, Booya F, Young BM, Fidler JL et al. CT enterography as a diagnostic tool in evaluating small bowel disorders: review of clinical experience with over 700 cases. Radiographics 2006;26(3): 641–57, discussion 57-62.
[4] Elsayes KM, Al-Hawary MM, Jagdish J, Ganesh HS, Platt JF. CT enterography: principles, trends, and interpretation of findings. Radiographics 2010;30(7):1955–70.
[5] Marin D, Boll DT, Mileto A, Nelson RC. State of the art: dual-energy CT of the abdomen. Radiology 2014;271(2):327–42.
[6] McCollough CH, Leng S, Yu L, Fletcher JG. Dual- and multi-energy CT: principles, technical approaches, and clinical applications. Radiology 2015;276(3):637–53.
[7] Ilangovan R, Burling D, George A, Gupta A, Marshall M, Taylor SA. CT enterography: review of technique and practical tips. Br J Radiol 2012;85(1015):876–86.
[8] Kilcoyne A, Kaplan JL, Gee MS. Inflammatory bowel disease imaging: current practice and future directions. World J Gastroenterol 2016;22(3):917–32.
[9] Riederer SJ, Mistretta CA. Selective iodine imaging using K-edge energies in computerized x-ray tomography. Med Phys 1977;4(6):474–81.
[10] Matsumoto K, Jinzaki M, Tanami Y, Ueno A, Yamada M, Kuribayashi S. Virtual monochromatic spectral imaging with fast kilovoltage switching: improved image quality as compared with that obtained with conventional 120-kVp CT. Radiology 2011;259(1):257–62.